

02/06/2020 – EPIC Online Technology Meeting on Medical Lasers

William Renard, PhD

CTO

**IRISIOME : French Aesthetic and medical devices manufacturer.
Expert in dermatological Laser treatments.**

I R I S I  M E

Æ S T H E T I C L A S E R D E V I C E S



Key steps IRISIOME

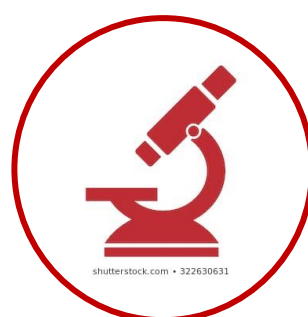Commercialization

Autumn 2020
On French market



Research & Development

Continuous clinical research and process development

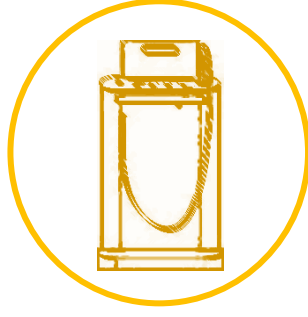


CREATION
Spin-off Univ. Bordeaux
2 brands



1st demo iMPulse

Mid 2018
First tests with Dermatologists
Proof of concept



Private fundraising

Nov.2018



IRISIOME Today:


10 people
Some partnerships:



IMPulse+ with patented technology




PATENTED




Our technology: 20 ps pulses delivered within a burst

Athermic process
Painless with fewer side effects



All fibered technology

Light handpiece, easy to handle
Low service and lightweight system



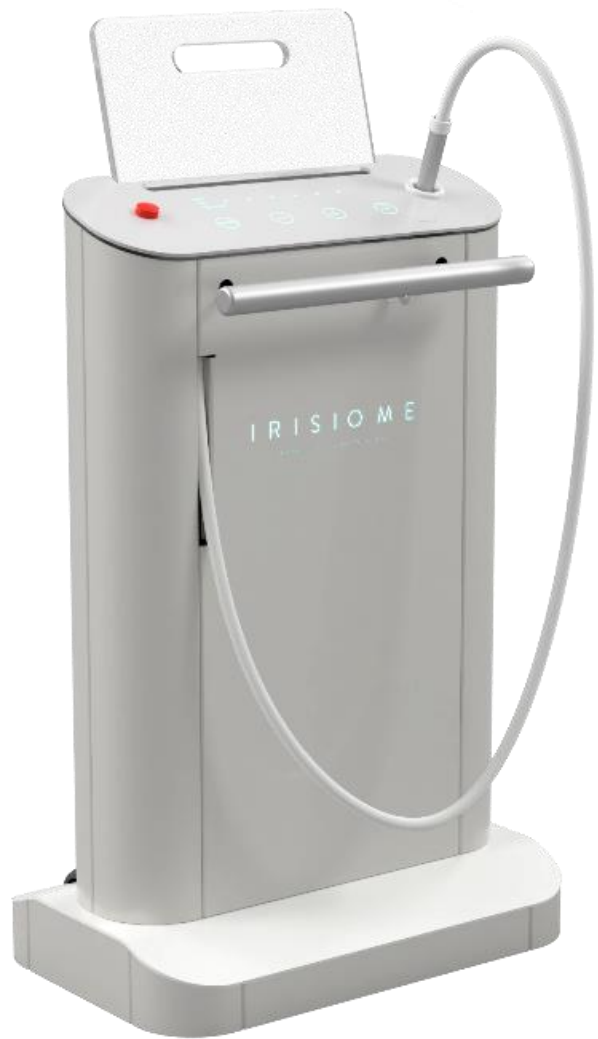Multiple indications

1064 nm / 532 nm
» Tattoo removal, treatment of vascular and pigmentary lesions, Depilation



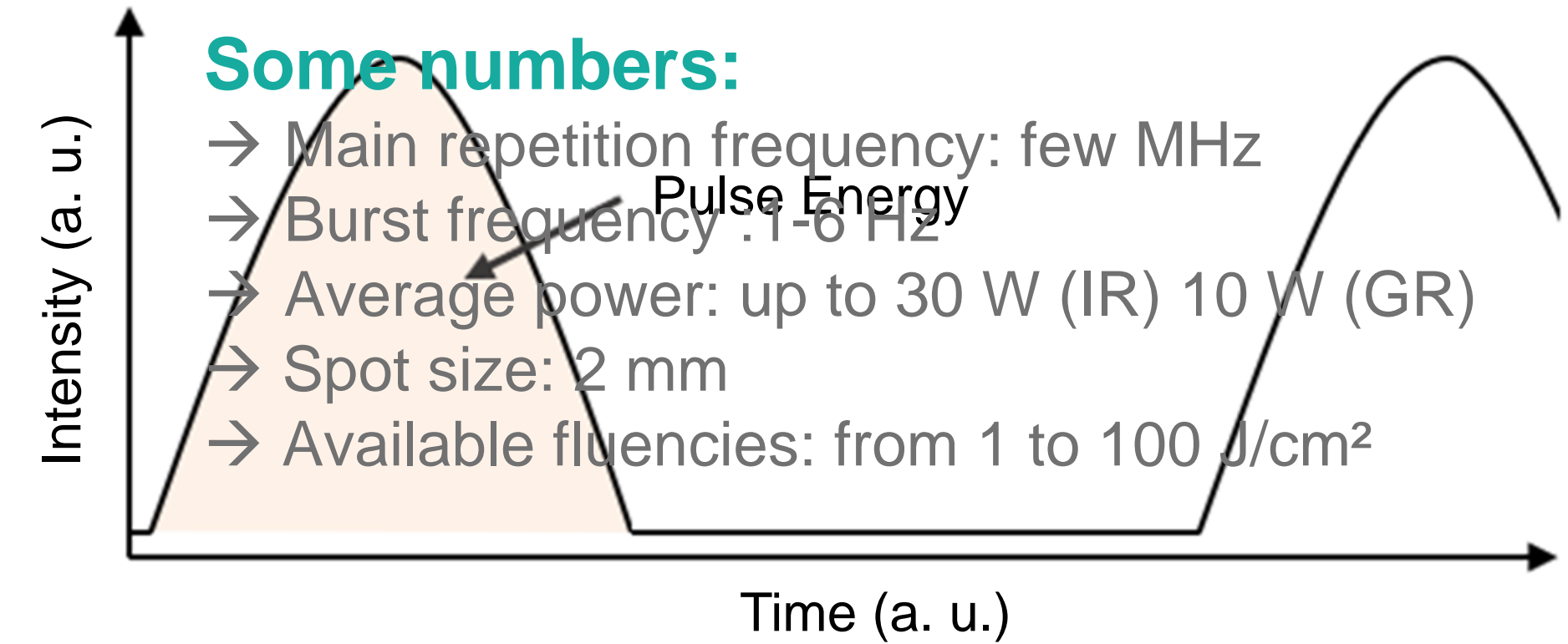
Mobile HMI (IPAD)

→ Easy to use and to follow patient treatments

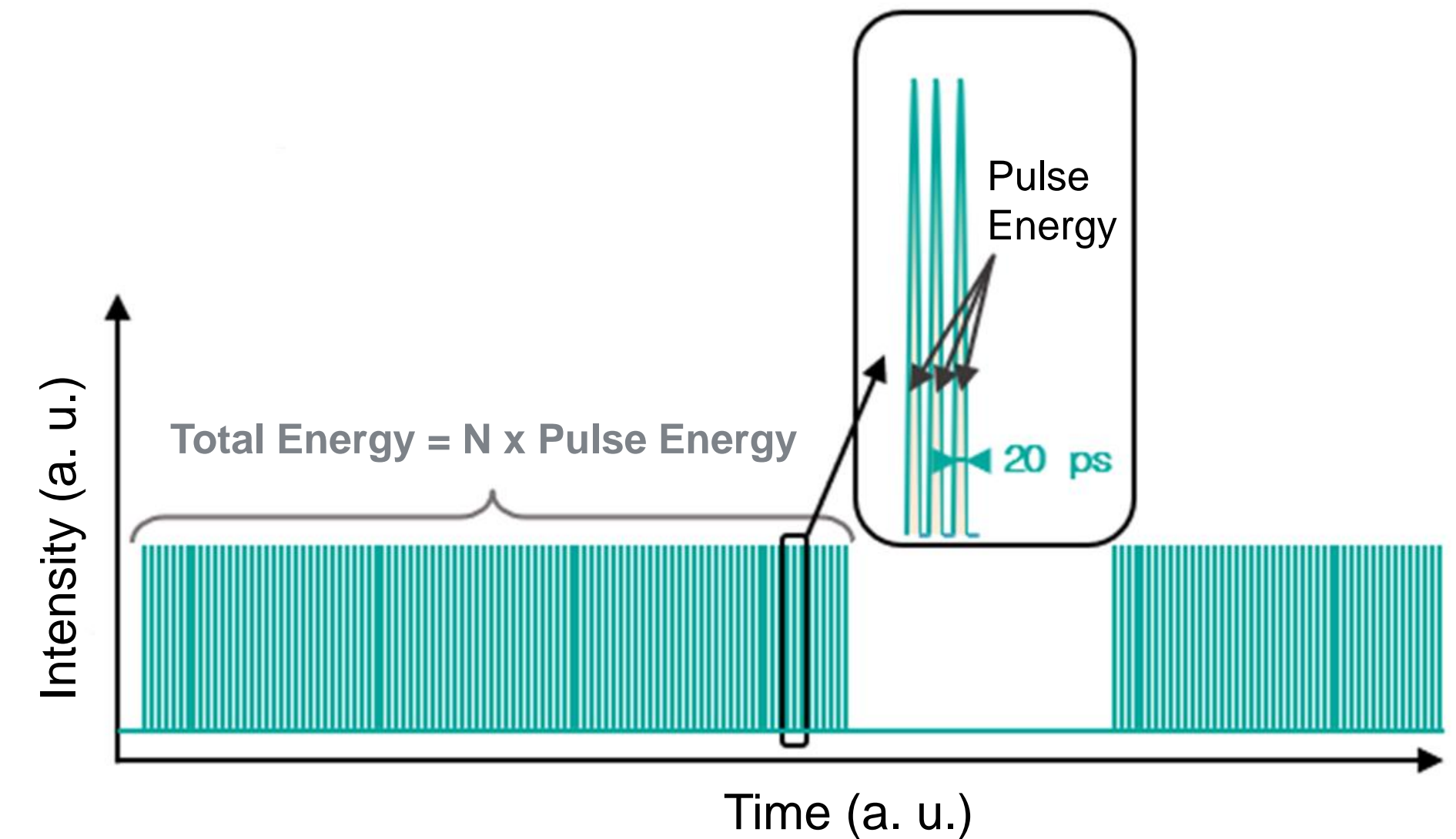


iMPulse+
BORN FROM SCIENCE







State of the Art



IRISIOME Technology



Some application examples with IMPULSE+

Tattoo removal	Vascular lesions	Pigment spot
 A close-up photograph of a person's skin with a black ink tattoo that reads "lej" in a cursive font, with a small heart symbol to the right of the letter "j".	 A photograph of a person's arm showing two small, reddish-purple vascular lesions. Each lesion is circled with a light blue line.	 A photograph of a person's skin with several reddish-brown pigment spots. Three spots are circled with light blue lines: two small circles at the top and one larger oval on the left side.
<p>Before</p>	<p>Before</p>	<p>Before</p>
 A close-up photograph of the same skin area as the "Before" image, but the tattoo has been significantly faded and is now barely visible as a light purple-grey mark.	 A photograph of the same arm as the "Before" image, showing the same two vascular lesions. The larger lesion is now circled with a light blue line, and the smaller one is also circled. The lesions appear less prominent than before.	 A photograph of the same skin area as the "Before" image, showing the same three pigment spots. The spots are still present but appear slightly less intense in color.
<p>After 8 treatments</p>	<p>After 1 treatment</p>	<p>After 1 treatment</p>

EPIC question: What can they do for you? What can you do for them?

What can YOU do for US ?

New European/international collaborations:

- To help us developing our understanding with Laser and skin interaction,
- To find tools to diagnostic and measure skin phototype and/or ink concentration,
- To provide to the community more and stronger scientific results.

What can WE do for YOU ?

- We can provide Laser tools for aesthetic markets,
- We are developing our expertise on uses of Laser for aesthetic applications.

- ... so I'm sure we can also help you in this field.

We are opened on discussions, please contact me:

William Renard, renard@irisiome.com

I R I S I O M E

ÆSTHETIC LASER DEVICES

The end. Thanks for watching!

